MEDISTIM

Case Report

Transit Time Flow Measurement assists intra-operative decision making

Medistim TRAM Flap Surgery Case Report
Jesse C. Selber, MD, Assistant Professor
Department of Plastic Surgery, The University of Texas MD Anderson Cancer Center

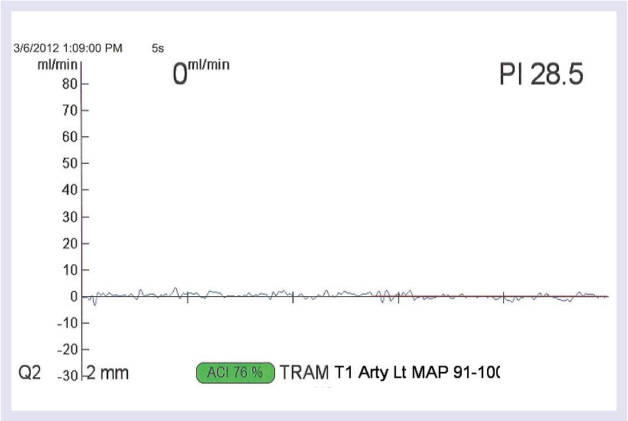

Figure 1. TTFM indicated no arterial flow with a high PI (pulsitility index) immediately following anastomosis and reperfusion

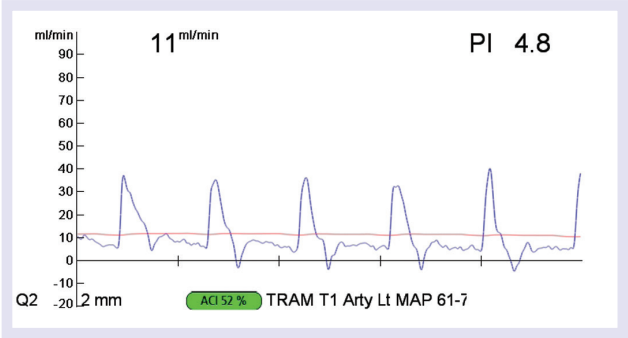

Figure 2. TTFM indicated improved arterial flow after anastomotic revision

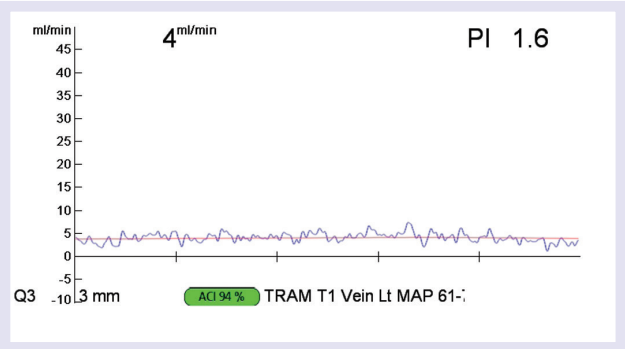

Figure 3. TTFM indicated improved venous flow after anastomotic revision

Transit Time Flow Measurement (TTFM) provides valuable information about flow characteristics and can impact clinical decision-making during free tissue transfer for reconstructive surgery.

Patient

A 39-year-old female with stage IIIA breast cancer underwent delayed unilateral reconstruction with a muscle-sparing TRAM (transverse rectus abdominus muscle) flap following radiation therapy.

Procedure

After an uneventful flap harvest and recipient vessel exposure, microvascular anastomoses were completed between the deep inferior epigastric and internal mammary vessels.

Despite straightforward anastomoses, upon clamp release, perfusion of the flap was uncertain. Clinical examination revealed a weak pulse in the pedicle and bleeding at the edges of the dermal flap.
The situation presented the surgeon with two options: either wait and observe the situation with the hope of improvement, or revise the anastomosis. At this point TTFM was performed and demonstrated no arterial flow with a high PI (pulsitility Index) (Fig. 1).

The decision was made to revise the anastomosis.

After anastomotic revision, the flap demonstrated excellent arterial (11 ml/min) and venous (4 ml/min) flow volumes with low PIs (4.8 and 1.6, respectively) (Fig.2 and 3.)

The patient's recovery was uneventful, with no evidence of necrosis at 4-month follow-up visit.

Discussion

Conclusion

TTFM provides novel physiologic flap data, identifies flawed anastomoses, and documents higher-flow venae comitantes. Using TTFM adds independent, objective measurements of blood flow, as well as functional documentation, enabling more informed decision-making than traditional methods alone. This information can reduce microvascular complications and improve patient outcomes.

In this case, TTFM provided clear-cut flow information about a flawed anastomosis where clinical exam alone was equivocal. This data allowed a rapid decision to be made with a good outcome. TTFM provides useful decision support in complex microvascular reconstruction.

References

1. Selber JC, Garvey P, Clemens et al. A Prospective Study of Transit Time Flow Volume (TTFV) Measurement for Intra-operative Evaluation and Optimization of Free Flaps. Plast Reconstr Surg 131(2):270-81, 2013.

For further information on the case, contact
marketing@medistim.com

Medistim ASA, Norway

For further information about scanning or TTFM measurements using VeriQ C, visit www.medistim.com.

CR00IN002 ver1 01/13